

Morphometry of the posterior clinoid process and dorsum sellae

Morfometrie processus clinoides posterior a dorsum sellae

Abstract

Aims: The posterior clinoid process (PCP) is a paired anatomic structure located in the middle cranial fossa on the superior surface of the sphenoid bone where it forms a bony eminence that is the lateral boundary of the dorsum sellae (DS). The aim of the study was to analyse PCP and DS morphometry in CT. **Materials and methods:** The study was based on 100 CT investigations of 54 women and 46 men aged 18–88 years (mean age 52.49 years). The PCP and DS morphometry was studied in coronal and sagittal planes. Data were analysed statistically in relation to patients' gender and age (group 1: up to 45 years, group 2: over 45 years). **Results:** The average width of the right and left PCP was 10.2 mm and 9.85 mm, resp., while the average height of the right and left PCP was 2.32 mm and 2.04 mm, resp. The thickness of the DS superior edge was 3.29 mm, and of the right and left PCP 4.28 mm and 4.31 mm, resp. Statistical calculations led to the conclusion that the right PCP was wider and thicker in men. Moreover, the DS superior edge is also thicker in men, and the left PCP is wider and higher in people over 45 years of age. **Conclusions:** The PCP and DS are different in men and women: 1. The right PCP is wider and thicker in men than in women; 2. The superior edge of the DS is thicker in men than in women; 3. The width and height of the left PCP reach higher values in patients over 45 years of age compared to those below 45 years of age.

Souhrn

Cíle: Processus clinoides posterior (PCP) je párová anatomická struktura situovaná ve střední jámě lební na horní straně klínové kosti, kde tvoří kostní výběžek, který představuje laterální hranici dorsum sellae (DS). Cílem studie bylo analyzovat morfometrii PCP a DS pomocí CT. **Materiály a metody:** Studie byla provedena na základě analýzy sta snímků pořízených CT u 54 žen a 46 mužů ve věku 18–88 let (průměrný věk 52,49 let). Na snímcích byla analyzována morfometrie PCP a DS v koronální a sagitální rovině. Získaná data byla statisticky analyzována ve vztahu k pohlaví a věku pacientů (skupina 1: pacienti do 45 let, skupina 2: pacienti starší 45 let). **Výsledky:** Průměrná šířka byla 10,2 mm u pravého PCP a 9,85 mm u levého PCP. Průměrná výška pravého PCP byla 2,32 mm a průměrná výška levého PCP 2,04 mm. Tloušťka horního okraje DS byla 3,29 mm a tloušťka pravého a levého PCP byla 4,28 mm a 4,31 mm. Statistické výpočty ukázaly, že pravý PCP je u mužů širší a silnější. Stejně tak horní okraj DS byl silnější u mužů a levý PCP byl širší a vyšší u osob starších 45 let. **Závěry:** Mezi PCP a DS mužů a žen existují rozdíly: 1. Pravý PCP je širší a silnější u mužů než u žen; 2. Horní okraj DS je silnější u mužů než u žen; 3. Šířka a výška levého PCP dosahovala vyšších hodnot u pacientů starších 45 let oproti skupině pacientů ve věku do 45 let.

The authors declare they have no potential conflicts of interest concerning drugs, products, or services used in the study.

Autoři deklarují, že v souvislosti s předmětem studie nemají žádné komerční zájmy.

The Editorial Board declares that the manuscript met the ICMJE "uniform requirements" for biomedical papers.

Redakční rada potvrzuje, že rukopis práce splnil ICMJE kritéria pro publikace zasílané do biomedicínských časopisů.

W. Ilków¹, M. Waligóra², M. Kunc³, M. Kucharzewski⁴

¹ Department of Neurosurgery, University Teaching Hospital in Opole, Poland

² Department of Medical Imaging, VITAL MEDIC, Kluczbork, Poland

³ Helimed Imaging Center, Opole, Poland

⁴ School of Medicine with the Division of Dentistry in Zabrze, Department and Division of Descriptive and Topographic Anatomy, Medical University of Silesia in Katowice, Zabrze Rokitnica, Poland



Wojciech Ilków
Department of Neurosurgery
University Teaching Hospital
in Opole
al. Witosa 26
45-401 Opole
Poland
e-mail: wojciechilkow@gmail.com

Accepted for review: 27. 12. 2017

Accepted for print: 21. 3. 2018

Key words

posterior clinoid process – dorsum sellae – computed tomography – sphenoid bone – base of the skull

Klíčová slova

procesus clinoides posterior – dorsum sellae – výpočetní tomografie – klínová kost – spodina lební

Introduction

The posterior clinoid process (PCP) is a paired anatomic structure located in the middle cranial fossa on the superior surface of the sphenoid bone where it forms a bony eminence that is the lateral boundary of the dorsum sellae (DS) [1].

As with the entire base of the skull, the embryogenesis of the PCP and DS is based on endochondral bone formation. These structures are not fully developed and ossified in neonates. Their secondary ossification occurs at approximately 4 years of age. The shape and size of the PCP and DS do not change significantly after puberty [2–4].

The PCP gives attachment for the petrosphenoidal ligament (ligament of Gruber) and interclinoid ligament. Moreover, together with the DS, it forms the posterior wall of the sella turcica which holds the pituitary gland [5–7].

Due to the location of the PCP and DS almost in the centre of the base of the skull and in the vicinity of vital anatomic structures, such as the brain stem, cavernous sinus, pituitary gland or basilar artery tip, these structures are a significant landmark used in both transcranial and endoscopic approaches in the treatment of pathologies located in this region, e.g. aneurysms of the distal segment of the basilar artery [8] (Fig. 1).

There are no precise data on the location of the border between the PCP and DS, and there are no morphometric characteristics of the PCP.

The aim of this study was to develop a clear morphometry-based definition of the PCP and indicate reproducible and useful measurement methods to evaluate the anatomy of the DS and PCP for preoperative planning.

Materials and methods

The study material comprised 100 anonymized CTA images of the head of 54 women and 46 men aged 18–88 years (mean age 52.49 years, standard deviation [SD] 18.64) diagnosed for headache. CT parameters: 16-row helical CT scanner GE BrightSpeed (GE medical Systems, Milwaukee, WI, USA), collimation of 1 mm, slice thickness of 0.625 mm, pitch 1.0., voltage 120 kV. Non-ionic contrast material (Omnipaque 350, GE Healthcare AS, Oslo) was injected into the median cubital vein at a rate of 3.5–4.5 mL/sec to the total volume of 80–100 mL using a power injector.

The study involved a retrospective analysis of scans without motion artefacts or foreign bodies, e.g. vascular clamps, without bony

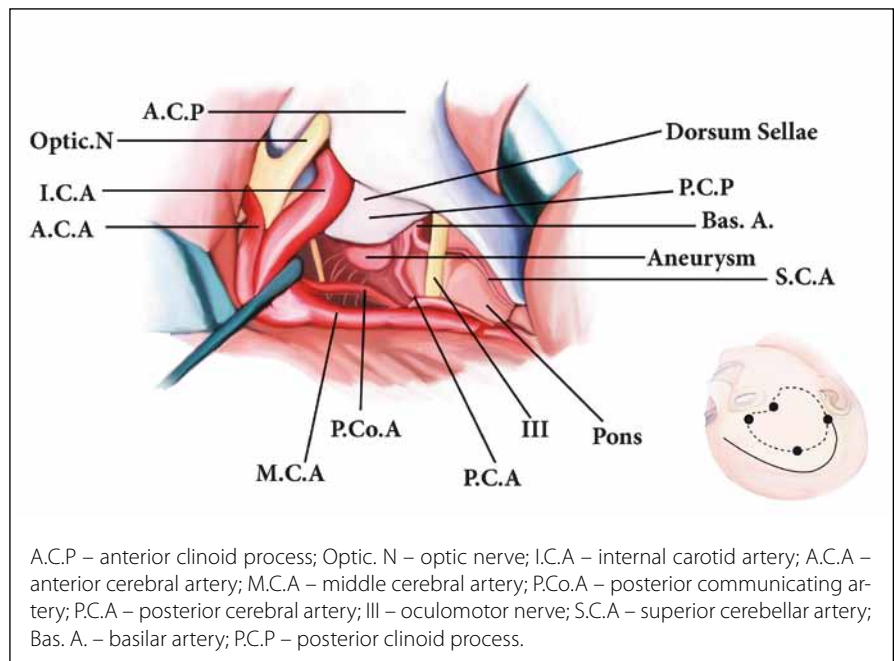


Fig. 1. The anatomy in the area of the right posterior clinoid process (the right pterional approach to basilar tip aneurysm).

Obr. 1. Anatomie v oblasti pravého processus clinoidae posterior (pterionální přístup zprava k aneurysmatu vycházejícímu z vrcholu bazilární artérie).

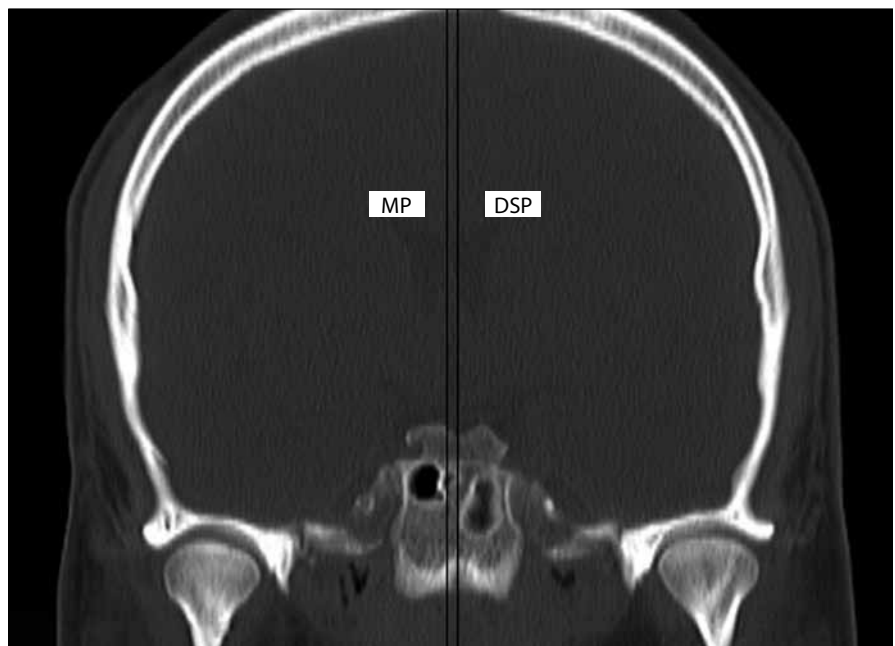


Fig. 2. Determination of the lowest DS point. The distance between the MP and DSP expressed in mm: the distance between the lowest DS point and the MP. Negative values were used when this point was located on the right, and positive values were used when it was located on the left of the MP. In the case of its medial location in the MP, the 0 value was assumed. DS – dorsum sellae; DSP – dorsum sellae plane; MP – midline plane

Obr. 2. Určení nejnižšího bodu DS. Vzdálenost mezi MP a DSP vyjádřená v mm: vzdálenost mezi nejnižším bodem DS a MP. Pokud se tento bod nacházel vpravo, byly použity záporné hodnoty, pokud se nacházel vlevo MP, je hodnota kladná. V případě mediální pozice v MP byla použita hodnota 0.

DS – dorsum sellae; DSP – rovina dorsum sellae; MP – středová rovina

bridges between the clinoid processes and without any intracranial pathology.

The measurements were taken using the bone window ($W = 1500$, $L = 300$) of CTA after multiplanar reconstruction based on methods presented in the following images.

Determination of the lowest DS point

In coronal sections, the following mutually parallel planes were selected: sagittal midline plane (MP) and sagittal dorsum sellae plane (DSP) that encompassed the lowest DS point (Fig. 2).

Width of the PCP

The following mutually parallel planes were selected in coronal sections: MP, sRPCP(w) (right sagittal posterior clinoid plane at the greatest width of the right PCP) and sLPCP(w) (left sagittal posterior clinoid plane at the greatest width of the left PCP) (Fig. 3).

Height of the PCP

The following mutually parallel transverse planes were selected in coronal sections: transverse plane (TP) encompassing the lowest DS point, tRPCP(h) (right transverse posterior clinoid plane at the greatest height of the right PCP) and tLPCP(h) (left transverse posterior clinoid plane at the greatest height of the left PCP) (Fig. 4).

Thickness of the PCP and DS

In the MP in sagittal sections, the following planes were selected: 1DS(t) (first oblique coronal plane in the Wackenheim clivus baseline) and its parallel 2DS(t) (second oblique coronal plane that encompassed the anterior-most point of the superior DS edge) (Fig. 5A, C).

Corresponding measurements were also taken in sagittal sections on both sides of the MP. On the right, in the sRPCP(h) (right sagittal posterior clinoid plane at the greatest height of the right PCP), mutually parallel coronal oblique planes were selected: R1PCP(t) (first sagittal right posterior clinoid plane in the Wackenheim clivus baseline) and its parallel plane R2PCP(t) (second sagittal right clinoid plane that encompassed the anterior-most point of the superior right PCP edge). On the left, however, in the sLPCP(h) (left sagittal posterior clinoid plane at the greatest height of the left PCP), mutually parallel coronal oblique planes were selected: L1PCP(t) (first sagittal left posterior clinoid plane in the Wackenheim clivus baseline) and its parallel plane L2PCP(t) (second sagittal right

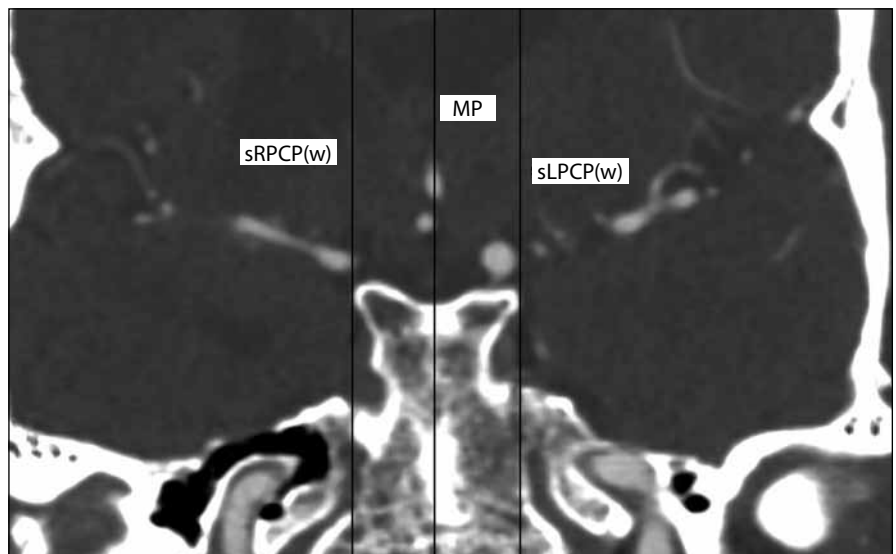


Fig. 3. Determination of the PCP width. The distance between the MP and sRPCP(w) expressed in mm: width of the right PCP. The distance between the MP and sLPCP(w) expressed in mm: width of the left PCP.

MP – midline plane; PCP – posterior clinoid process; sLPCP(w) – left sagittal posterior clinoid plane at the greatest width of the left PCP; sRPCP(w) – right sagittal posterior clinoid plane at the greatest width of the right PCP

Obr. 3. Určení šířky PCP. Vzdálenost mezi MP a sRPCP(w) vyjádřená v mm: výška pravého PCP. Vzdálenost mezi MP a sLPCP(w) vyjádřená v mm: šířka levého PCP.

MP – středová rovina; PCP – processus clinoidae posterior; sLPCP(w) – levá sagitální zadní klinoidní rovina na největší šířce levého PCP; sRPCP(w) – pravá sagitální zadní klinoidová rovina na největší šířce pravého PCP

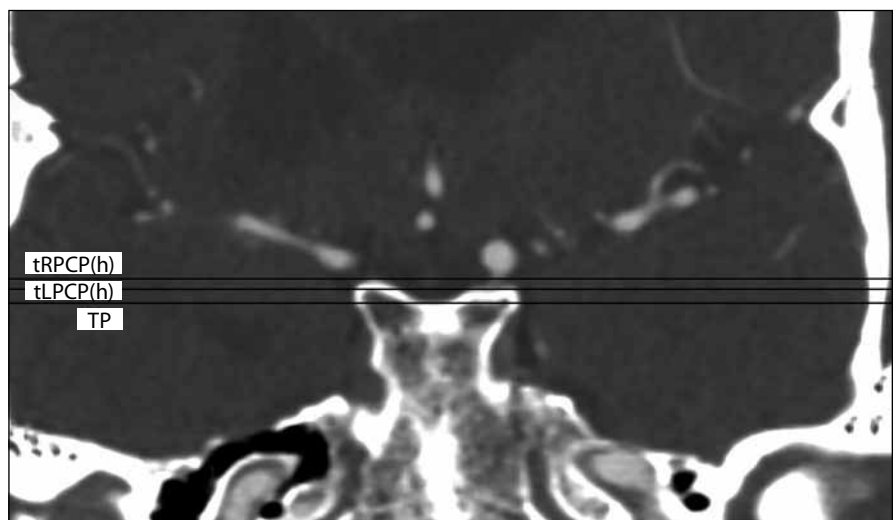


Fig. 4. Determination of the PCP height. The distance between the TP and tRPCP(h) expressed in mm: height of the right PCP. Distance between the TP and tLPCP(h) expressed in mm: height of the left PCP.

PCP – posterior clinoid process; tLPCP(h) – left transverse posterior clinoid plane at the greatest height of the left PCP; TP – transverse plane; tRPCP(h) – right transverse posterior clinoid plane at the greatest height of the right PCP

Obr. 4. Určení výšky PCP. Vzdálenost mezi TP a tRPCP(h) vyjádřená v mm: výška pravého PCP. Vzdálenost mezi TP a tLPCP(h) vyjádřená v mm: výška levého PCP.

PCP – processus clinoidae posterior; tLPCP(h) – levá příčná zadní klinoidová rovina v největší výšce levého PCP; TP – příčná rovina; tRPCP(h) – pravá příčná zadní klinoidová rovina v největší výšce pravého PCP

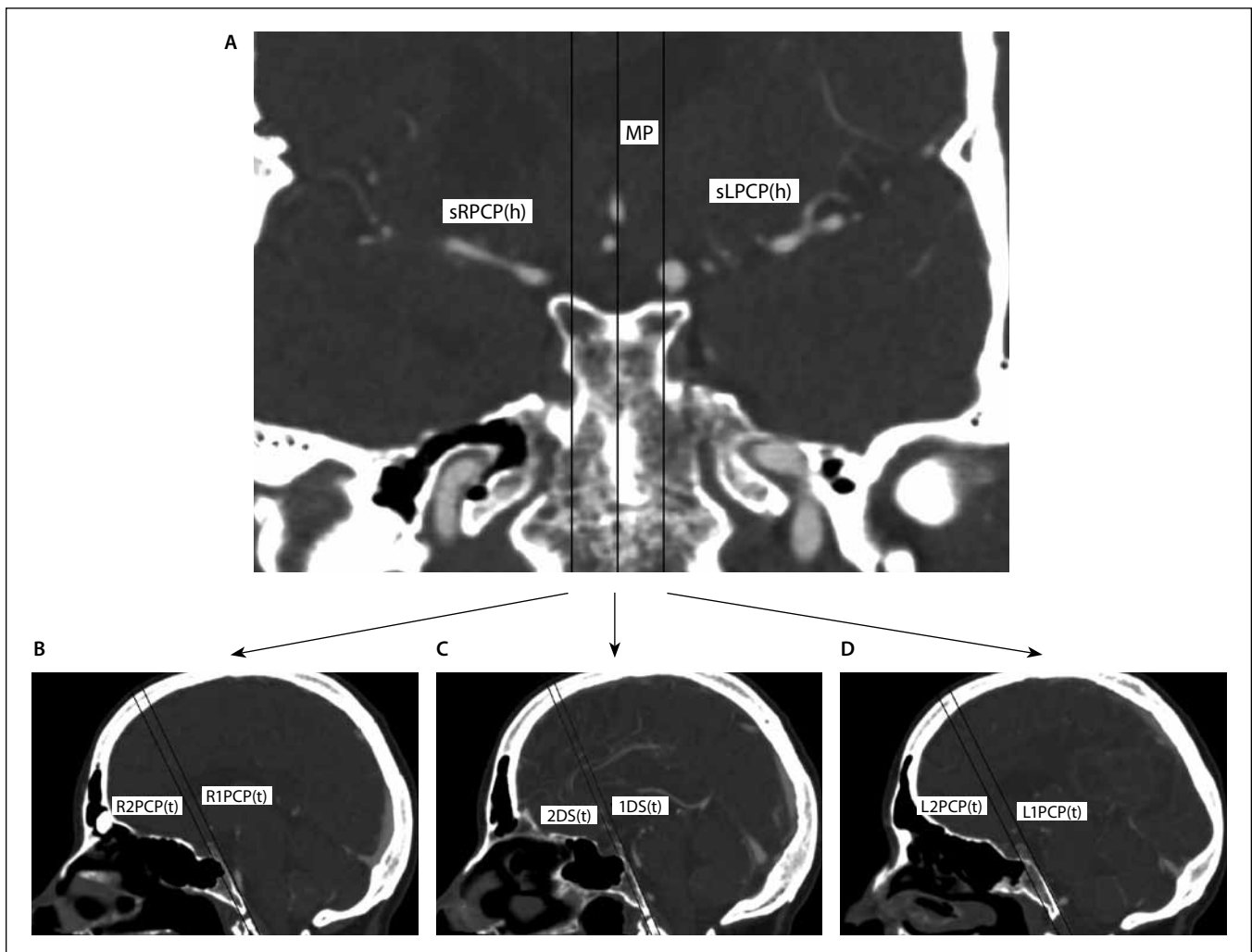


Fig. 5. Determination of the thickness of the PCP and DS.

A – CTA of the head; coronal section with marked planes [MP, sRPCP(h), sLPCP(h)] in which the thickness of the upper edge of the DS, the thickness of the right PCP and the thickness of the left PCP were measured, respectively.

B – Head CT angiography, sagittal section. Distance between the R1PCP(t) and R2PCP(t) expressed in mm: thickness of the right PCP.

C – Head CT angiography, sagittal section. Distance between the 1DS(t) and 2DS(t) expressed in mm: thickness of the superior edge of the DS.

D – Head CT angiography, sagittal section. Distance between the L1PCP(t) and L2PCP(t) planes expressed in mm: thickness of the left PCP.

1DS(t) – first oblique coronal plane in the Wackenheim clivus baseline; 2DS(t) – second oblique coronal plane that encompassed the anterior-most point of the superior dorsum sellae edge; DS – dorsum sellae; L1PCP(t) – first sagittal left posterior clinoid plane in the Wackenheim clivus baseline; L2PCP(t) – second sagittal right posterior clinoid plane that encompassed the anterior-most point of the superior left PCP edge; MP – midline plane; PCP – posterior clinoid process; R1PCP(t) – first sagittal right posterior clinoid plane in the Wackenheim clivus baseline; R2PCP(t) – second sagittal right clinoid plane that encompassed the anterior-most point of the superior right PCP edge; sLPCP(h) – left sagittal posterior clinoid plane at the greatest height of the left PCP; sRPCP(h) – right sagittal posterior clinoid plane at the greatest height of the right PCP

Obr. 5. Určení tloušťky PCP a DS.

A – CT angiografie hlavy; koronální řez s vyznačenými rovinami [MP, sRPCP(h), sLPCP(h)], ve kterých byla měřena tloušťka horního okraje DS, tloušťka pravého PCP a tloušťka levého PCP.

B – CT angiografie hlavy, sagitální řez. Vzdálenost mezi R1PCP(t) a R2PCP(t) vyjádřená v mm: tloušťka pravého PCP.

C – CT angiografie hlavy, sagitální řez. Vzdálenost mezi 1DS(t) a 2DS(t) vyjádřená v mm: tloušťka horního okraje DS.

D – CT angiografie hlavy, sagitální řez. Vzdálenost mezi rovinami L1PCP(t) a L2PCP(t) vyjádřená v mm: tloušťka levého PCP.

1DS(t) – první šikmá korunní rovina v základní lince Wackenheim clivus; 2DS(t) – druhá šikmá korunní rovina, která obklopovala přední část nejvyššího okraje hřbetního svazku; DS – dorsum sellae; L1PCP(t) – první sagitální levá posteriorní klinoidní rovina v základní hodnotě Wackenheim clivus; L2PCP(t) – druhá sagitální pravá posteriorní klinoidní rovina, která obklopovala přední část nejvyšší levé strany PCP; MP – středová rovina; PCP – processus clinoidae posterior; R1PCP(t) – první sagitální pravá posteriorní klinoidová rovina v základní hodnotě Wackenheim clivus; R2PCP(t) – druhá sagitální pravá klinoidová rovina, která zahrnovala přední část nejvyšší pravé strany PCP; sLPCP(h) – levá sagitální zadní klinoidní rovina v největší výšce levého PCP; sRPCP(h) – pravá sagitální zadní klinoidová rovina v největší výšce pravého PCP

Tab. 1. Symmetry of the lowest DS point in relation to the MP.

symmetry of the lowest DS point in relation to the MP	women		men
	N	%	N
right	26	48.1	22
in the MP	13	24.1	11
left	15	27.8	13
chi square	0.0029		
p	0.9986		

DS – dorsum sellae; MP – midline plane

posterior clinoid plane that encompassed the anterior-most point of the superior left PCP edge) (Fig. 5B, D).

Statistical analysis

Statistical calculations were performed in the PQStat version 1.6.2.901 (PQStat Software, Poznań/Plewiska, Poland).

The PCP and DS morphometric results were compared between women and men using the Student's t-test. The symmetry of the lowest DS point in relation to the MP was analysed with the chi-squared test. The PCP and DS morphometry relative to age was analysed with the Student's t-test for independent samples.

The tested probability was deemed significant at $p < 0.05$, and highly significant at $p < 0.01$.

Results

Symmetry of the lowest DS point in relation to the MP

In the studied group (N = 100), the analysis of the lowest DS point symmetry in relation to the MP revealed the right position most frequently (48 cases; 26 women, 22 men). Detailed results are presented in Tab. 1.

There were no significant correlations ($p > 0.05$) between the analysed symmetry and gender.

Location of the lowest DS point in relation to the MP

In our set (N = 100), the average distance between the lowest DS point and the MP plane was -0.35 mm. The average distance between the lowest DS point and the MP plane was -0.37 mm in women (N = 54) and

Tab. 2. Location of the lowest DS point in relation to the MP.

distance between planes in mm	arithmetic mean	standard deviation	min	median	max	Student's t-test
MP – DSP N = 100	-0.35	1.74	-7.3	0	4.8	$p = 0.9227$
MP – DSP N = 54 – women	-0.37	1.91	-7.3	0	4.8	
MP – DSP N = 46 – men	-0.33	1.52	-2.8	0	3.1	

DS – dorsum sellae; DSP – dorsum sellae plane; MP – midline plane

Tab. 3. Width of the PCP.

distance between planes in mm	arithmetic mean	standard deviation	min	median	max	Student's t-test
Width of the right PCP						
MP – sRPCP(w) N = 100	10.2	1.52	5.6	10	14.6	$p = 0.0004$
MP – sRPCP(w) N = 54 – women	9.71	1.53	5.6	9.5	12.7	
MP – sRPCP(w) N = 46 – men	10.78	1.31	-8.1	10.95	14.6	
Width of the left PCP						
MP – sLPCP(w) N = 100	9.85	1.63	6.4	10	13.4	$p = 0.2983$
MP – sLPCP(w) N = 54 – women	9.74	1.67	6.4	9.95	13.4	
MP – sLPCP(w) N = 46 – men	9.99	1.61	6.9	10.2	12.4	

MP – midline plane; PCP – posterior clinoid process; sLPCP(w) – left sagittal posterior clinoid plane at the greatest width of the left PCP; sRPCP(w) – right sagittal posterior clinoid plane at the greatest width of the right PCP.

-0.33 mm in men (N = 46). Detailed results are presented in Tab. 2.

Negative values were assumed when the lowest DS point was located on the right of the MP, and positive values were used when this point was located on the left of the MP. The 0 value was assumed for the lowest DS point located in the MP.

There were no significant correlations ($p > 0.05$) between the location of the lowest DS point and gender.

Width of the PCP

The average width of the right and left PCP was 10.20 mm and 9.85 mm, resp. The

average width of the right PCP was 9.71 mm in women (N = 54) and 10.78 mm in men (N = 46). Detailed results are presented in Tab. 3.

As for the width of the right PCP, the results differed depending on gender in a highly significant way ($p < 0.01$): higher measurements were obtained in men.

Height of the PCP

The average height of the right and left PCP was 2.32 mm and 2.04 mm, resp. The average height of the right PCP was 2.28 mm in women (N = 54) and 2.37 mm in men

Tab. 4. Height of the PCP.

distance between planes in mm	arithmetic mean	standard deviation	min	median	max	Student's t-test
Height of the right PCP						
TP – tRPCP(h) N = 100	2.32	1.13	0.2	2.05	6.2	p = 0.8119
TP – tRPCP(h) N = 54 – women	2.28	0.99	0.5	2.05	5.9	
TP – tRPCP(h) N = 46 – men	2.37	1.29	0.2	2.15	6.2	
Height of the left PCP						
TP – tLPCP(h) N = 100	2.04	1.11	0.4	1.8	6.9	p = 0.4506
TP – tLPCP(h) N = 54 – women	2.07	0.97	0.8	1.85	6.1	
TP – tLPCP(h) N = 46 – men	2.01	1.25	0.4	1.6	6.9	

PCP – posterior clinoid process; TP – transverse plane; tLPCP(h) – left transverse posterior clinoid plane at the greatest height of the left PCP; tRPCP(h) – right transverse posterior clinoid plane at the greatest height of the right PCP.

Tab. 5. Thickness of the superior DS edge.

distance between planes in mm	arithmetic mean	standard deviation	min	median	max	Student's t-test
1DS(t) – 2DS(t) N = 100	3.29	1.06	1.2	3.05	7	p = 0.0106
1DS(t) – 2DS(t) N = 54 – women	3.04	0.99	1.2	2.9	6	
1DS(t) – 2DS(t) N = 46 – men	3.58	1.08	1.7	3.5	7	

DS – dorsum sellae; 1DS(t) – first oblique coronal plane in the Wackenheim clivus baseline; 2DS(t) – second oblique coronal plane that encompassed the anterior-most point of the superior DS edge.

(N = 46). Detailed results are presented in Tab. 4.

The results show no significant differences depending on gender ($p > 0.05$).

Thickness of the superior DS edge

The average thickness of the superior DS edge was 3.29 mm. The average thickness of the superior DS edge was 3.04 mm in women (N = 54) and 3.58 mm in men (N = 46). Detailed results are presented in Tab. 5.

The results differed significantly depending on gender ($p < 0.05$): higher measurements were obtained in men.

Thickness of the PCP

The average thickness of the right and left PCP was 4.28 mm and 4.31 mm, resp. The average thickness of the right PCP was 4.01 mm in women (N = 54) and 4.60 mm in men (N = 46). Detailed results are presented in Tab. 6.

As for the right PCP thickness, the results differed depending on gender in a highly significant way ($p < 0.01$): higher measurements were obtained in men.

The PCP and DS morphometry depending on age

The results were also analysed statistically in relation to age in two groups of patients

(group 1: up to 45 years of age, group 2: over 45 years of age).

As for the width of the left PCP, the results differed significantly between the age groups ($p = 0.0449$; Student's t-test). The obtained values were higher in group 2 (average 10.10 mm) compared to group 1 (average 9.41 mm).

As for the height of the left PCP, the results also differed significantly between the age groups ($p = 0.0467$; Student's t-test). The obtained values were higher in group 2 (average 2.21 mm) compared to group 1 (average 1.75 mm).

In the remaining analysed scales, the PCP and DS morphometry showed no significant differences ($p > 0.05$) depending on age.

Discussion

There are a number of pathologies that can develop in the region of the PCP and DS, including benign tumours, such as: meningioma, neuroma or adenoma, and malignant lesions, such as: chordoma, chondrosarcoma or metastatic tumours. Moreover, vascular pathologies, the most common of which is basilar tip aneurysm, can also occur in this region [1,9,10].

According to Fernandez-Miranda et al, the morphometry of the PCP and DS determines conditions in the narrow and deep surgical fields. These bony structures might form an obstacle restricting free access to pathologies located deeper, e.g. to basilar tip aneurysms [1,4]. For this reason, they might be reduced during the procedure using a microdrill. In the case of PCP removal, this manoeuvre is called posterior clinoidectomy and has been considered useful in the treatment of basilar tip aneurysms by e.g. Dolenc et al [11–13].

Silva et al emphasises the significance of posterior clinoidectomy performed with an endoscope for improved access to pathologies located in the region of the PCP [14]. By contrast with well-known anatomy of the anterior clinoid process, there are few reports that describe the morphometry of the PCP and DS based on reproducible methods [8,15,16].

Salma et al analysed the anatomy of the PCP region based on 3D reconstructions of 36 cadaveric head CT images. The study presents the distance between the PCP and the remaining anatomic structures that are crucial in surgery of the base of the skull, such as the crista galli, superior orbital fissure and foramen rotundum [7].

Cheng et al analysed the morphometry of the PCP based on head CT images of 120 patients (68 women and 52 men). The studies were conducted in coronal, sagittal and transverse sections using multiplanar reconstruction.

The greatest PCP width was obtained in the PCP uppermost layers (the PCP width was also tested in the basal and middle layers). The average width of the right and left PCP was 9.32 mm (SD 0.55, range 7.38–11.43 mm) and 9.23 mm (SD 0.53, range 7.02–11.56), resp. [8].

The present study, based on head CTA conducted in 100 patients (54 women, 46 men), yielded comparable results: the average width of the right PCP was 10.2 mm (SD 1.52, range 5.6–14.6 mm), and the average width of the left PCP was 9.85 mm (SD 1.63, range 6.4–13.4 mm). Moreover, the highest PCP thickness values (measured in middle PCP layers) obtained by Cheng were compared with the results of the present study. In the study by Cheng et al, the average thickness of the right PCP was 4.34 mm (SD 0.32, range 3.88–4.94 mm), and the average value on the left side was 4.31 mm (SD 0.34, range 3.75–4.87 mm). In our study, the average thickness of the right PCP was 4.28 mm (SD 1.08, range 2.4–7.7 mm), and the average value on the left side was 4.31 mm (SD 1.09, range 1.9–7.8 mm).

According to Cheng et al, the average height of the right PCP was 8.49 mm (SD 0.51, range 6.59–9.21 mm), and the average value on the left side was 8.36 mm (SD 0.52, range 7.05–9.81 mm) [8]. The height of the PCP in our study was lower than the respective values presented by Cheng et al. In our material, the average height of the right and left PCP was 2.32 mm (SD 1.13, range 0.2–6.2 mm) and 2.04 mm (SD 1.11, range 0.4–6.9), resp. These discrepancies may result from the difficulties in determining the height of the PCP (i.e., the boundary between the PCP and DS) and from the usage of a different measuring method. Cheng et al found statistically significant differences in the analysed measurements between the right and left sides [8]. In the present study, the measurement results were additionally analysed statistically in relation to age.

We decided to define the PCP as the elevation of bone above the lowest DS point. Because the transverse diameter of the PCP is, according to us, measured from the lowest DS point, the whole DS is

Tab. 6. Thickness of the PCP.

distance between planes in mm	arithmetic mean	standard deviation	min	median	max	Student's t-test
Thickness of the right PCP						
R1PCP(t) – R2PCP(t) N = 100	4.28	1.08	2.4	4.1	7.7	p = 0.0069
R1PCP(t) – R2PCP(t) N = 54 – women	4.01	0.84	2.5	4	7.6	
R1PCP(t) – R2PCP(t) N = 46 – men	4.6	1.24	2.4	4.4	7.7	
Thickness of the left PCP						
L1PCP(t) – L2PCP(t) N = 100	4.31	1.09	1.9	4.15	7.8	p = 0.1264
L1PCP(t) – L2PCP(t) N = 54 – women	4.16	1.03	1.9	4	7.8	
L1PCP(t) – L2PCP(t) N = 46 – men	4.5	1.15	2.3	4.6	7.4	

L1PCP(t) – first sagittal left posterior clinoid plane in the Wackenheim clivus baseline; L2PCP(t) – second sagittal right posterior clinoid plane that encompassed the anterior-most point of the superior left PCP edge; PCP – posterior clinoid process; R1PCP(t) – first sagittal right posterior clinoid plane in the Wackenheim clivus baseline; R2PCP(t) – second sagittal right clinoid plane that encompassed the anterior-most point of the superior right PCP edge

composed of two PCPs. Our concept of thickness addresses the problem of the location of the border between the lower contour of the PCP and the lateral border of the DS. Due to its variability, it is very difficult to assess this point well. The thickness of the PCP determines the diameter of a drill and informs a neurosurgeon about how much bone lies ahead during drilling.

Owing to the applied measurement methods, the authors obtained results previously unseen in the literature. This helped to precisely determine the PCP and DS morphometry, which might be useful in planning surgical accesses to pathologies in this region.

Conclusions

The PCP and DS are different in men and women:

1. The right PCP is wider and thicker in men than in women.
2. The superior edge of the DS is thicker in men than in women.
3. The width and height of the left PCP reach higher values in patients over 45 years of age compared to those below 45 years of age.

References

1. Fernandez-Miranda JC, Gardner PA, Rastelli MM Jr et al. Endoscopic endonasal transclivous posterior clinoidectomy with interdural pituitary transposition. *J Neurosurg* 2014; 121(1): 91–99. doi: 10.3171/2014.3.JNS131865.
2. Berger PE, Harwood-Nash DC, Fitz CR. The dorsum sellae in infancy and childhood. *Pediatr Radiol* 1976; 4(4): 214–220. doi: 10.1007/BF02461527.
3. Tubbs RS, Salter EG, Oakes WJ. Quantitation of and measurements utilizing the sphenoid ridge. *Clin Anat* 2007; 20(2): 131–134. doi: 10.1002/ca.20255.
4. Youssef AS, van Loveren HR. Posterior clinoidectomy: dural tailoring technique and clinical application. *Skull Base* 2009; 19(3): 183–191. doi: 10.1055/s-0028-1096196.
5. Icke C, Ozer E, Arda N. Microanatomical characteristics of the petrosphenoidal ligament of Gruber. *Turk Neurosurg* 2010; 20(3): 323–327. doi: 10.5137/1019-5149.JTN.2921-10.0.
6. Ozdogmus O, Saka E, Tulay C et al. Ossification of interclinoid ligament and its clinical significance. *Neuroanat* 2003; 2: 25–27.
7. Salma A, Baidya NB, Wendt B et al. Qualitative and quantitative radio-anatomical variation of the posterior clinoid process. *Skull Base* 2011; 21(6): 373–378. doi: 10.1055/s-0031-1287678.
8. Cheng Y, Chen Y, Zhou Z et al. Anatomical study of posterior clinoid process (PCP) and its clinical meanings. *J Craniofac Surg* 2015; 26(2): 537–540. doi: 10.1097/SCS.0000000000001517.
9. Sodhi HBS, Singla N, Gupta SK. Posterior clinoid meningioma: a case report with discussion on terminology and surgical approach. *Surg Neurol Int* 2015; 6: 21. doi: 10.4103/2152-7806.151261.
10. Yonekawa Y, Khan N, Imhof HG et al. Basilar bifurcation aneurysms. Lessons learnt from 40 consecu-

tive cases. Acta Neurochir Suppl 2005; 94: 39–44. doi: 10.1007/3-211-27911-3_7.

11. Chanda A, Nanda A. Anatomical study of the orbitozygomatic transsellar-transcavernous-transclinoidal approach to the basilar artery bifurcation. J Neurosurg 2002; 97(1): 151–160. doi: 10.3171/jns.2002.97.1.0151.

12. Dolenc VV, Skrap M, Sustersic J et al. A transcavernous-transsellar approach to the basilar tip aneu-

rysms. Br J Neurosurg 1987; 1(2): 251–259. doi: 10.3109/02688698709035309.

13. Tang CT, Baidya NB, Tseng KY et al. Posterior clinoid process as a landmark in current endoscopic-assisted neurosurgical approaches. Formos J Surg 2012; 45(2): 45–50. doi: 10.1016/j.fjs.2012.01.002.

14. Silva D, Attia M, Kandasamy J et al. Endoscopic endonasal posterior clinoidectomy. Surg Neurol Int 2012; 3: 64. doi: 10.4103/2152-7806.97008.

15. Dagtekin A, Avci E, Uzmansel D et al. Microsurgical anatomy and variations of the anterior clinoid process. Turk Neurosurg 2014; 24(4): 484–493. doi: 10.5137/1019-5149.JTN.8738-13.1.

16. Hunnargi S, Ray B, Pai SR et al. Metrical and non-metrical study of anterior clinoid process in South Indian adult skulls. Surg Radiol Anat 2008; 30(5): 423–428. doi: 10.1007/s00276-008-0346-1.

Česká neurologická společnost ČLS JEP

Česká neurologická společnost (ČNS) je součástí České lékařské společnosti Jana Evangelisty Purkyně (www.cls.cz).

Členem společnosti může stát lékař, farmaceut, případně jiný pracovník ve zdravotnictví a příbuzném oboru, který souhlasí s posláním a cíli ČLS JEP a zaváže se přispívat k jejich plnění. Každý může být členem více odborných společností.

Jak se stát členem ČNS?

- vyplňte přihlášku na webových stránkách ČNS www.czech-neuro.cz, registrovat se zároveň můžete také do jednotlivých sekcí ČNS
 - po odeslání registrace získáte na e-mail potvrzení o úspěšném odeslání Vaší přihlášky
- schvalování žádostí o členství probíhá vždy na nejbližší výborové schůzi ČNS, o přijetí Vás bude informovat sekretariát ČNS (sekretariat@czech-neuro.cz)

Co vám členství v ČNS přinese?

- předplatné časopisu Česká a slovenská neurologie a neurochirurgie
 - pravidelný elektronický zpravodaj s novinkami
- zvýhodněné podmínky účasti na pravidelném neurologickém sjezdu a jiných akcích
 - možnost zúčastnit se soutěže o nejlepší neurologické publikace

Změny údajů

V případě změny Vašich údajů (jména, adresy, telefonu, e-mailu apod.) ji, prosím, nahlaste členské evidenci sekretariátu ČNS sekretariat@czech-neuro.cz. Změna bude nahlášena automaticky také vydavateli časopisu Česká a slovenská neurologie a neurochirurgie a Centrální evidenci členů ČLS JEP.